

<https://doi.org/10.18233/apm.v44i5.2507>

## Lymphangiomatous polyp of the palatine tonsil in children.

### Pólipo linfangiomatoso de la amígdala palatina en niños

Marta Rodríguez Anzules,<sup>1</sup> Enrique Guillén Lozada,<sup>1</sup> Luis Blasco Santana,<sup>2</sup> Margarita Bartolomé Benito,<sup>1</sup> Ángel Moreno-Juara,<sup>1</sup> Saturnino Santos Santos<sup>1</sup>

#### Abstract

**BACKGROUND:** Lymphangiomatous polyp is a very uncommon benign and congenital lesion that appears mainly in the head and neck area. The polyp arises due to a vascular and lymphatic malformation. Medical publications indicate that the number of cases in children is unknown.

**CLINICAL CASE:** In this paper, two different cases will be presented; one of these dates from 2018 (a 6-year-old boy) and the other one from 2021, the first younger clinical case (a 3-year-old girl) of multiple and bilateral lymphangiomatous polyps of the palatine tonsils. Both these cases were diagnosed during routine procedures at our hospital which will be explained below.

**CONCLUSIONS:** The clinical suspicion is based on medical history, symptoms (dysphagia, foreign body sensation) and the oral cavity examination, but the definitive diagnosis is histopathological. The treatment consists of a tonsillectomy or a simple surgical excision. Regarding the images (CT-scan or MRI) there is controversy over whether to perform these or not. Although the clinical behavior of tonsillar lymphangiomatous polyps is unknown and unclear, our reported cases did not have presence of a malignancy or growth.

**KEYWORDS:** Lymphangioma; Polyp; Palatine tonsil.

#### Resumen

**ANTECEDENTES:** El pólipo linfangiomatoso es una lesión benigna y congénita poco frecuente, que suele aparecer en la cabeza y el cuello. El pólipo se origina por alguna malformación vascular y linfática. Hasta el momento se desconoce la cantidad de casos en niños con esta afectación.

**CASO CLÍNICO:** Se exponen dos casos clínicos diferentes: uno data de 2018 (un niño de 6 años) y el otro de 2021, el primero se trata de una paciente más joven (una niña de 3 años), con múltiples pólipos linfangiomatosos y bilaterales de las amígdalas palatinas. Ambos casos fueron diagnosticados durante los procedimientos de rutina en el hospital.

**CONCLUSIONES:** La sospecha clínica se basa en la historia clínica, los síntomas (disfagia, sensación de cuerpo extraño) y la exploración de la cavidad oral; sin embargo, el diagnóstico definitivo se establece con el estudio histopatológico. El tratamiento consiste en amigdalectomía o escisión quirúrgica simple. En cuanto a los estudios de imagen (tomografía computada o resonancia magnética), aún se discute la conveniencia de realizarlos o no. Aunque el comportamiento clínico de los pólipos linfangiomatosos amigdalinos es desconocido y poco claro, los casos aquí reportados no mostraron malignidad ni crecimiento.

**PALABRAS CLAVE:** Linfangioma; pólipo; amígdala palatina.

<sup>1</sup> Department of Otolaryngology.

<sup>2</sup> Department of Pathological Anatomy. Niño Jesús University Children's Hospital, Madrid, Spain.

**Received:** July 7<sup>th</sup>, 2021

**Accepted:** September 18<sup>th</sup>, 2023

#### Correspondence

Marta Rodríguez Anzules  
martarodriguezanzules@gmail.com

**This article should be cited as:** Rodríguez-Anzules M, Guillén-Lozada E, Blasco-Santana L, Bartolomé-Benito M, Moreno-Juara A, Santos-Santos S. Lymphangiomatous polyp of the palatine tonsil in children. Acta Pediatr Mex 2023; 44 (5): 371-378.

## INTRODUCTION

Benign tumors in tonsils are more infrequent than malignant tumors.<sup>1</sup> Lymphangioma is a benign congenital tumor that is produced when a vascular and lymphatic malformation arises in the tissues. The places where they are more prevalent are: in the floor of the mouth, tongue and cheek (35%), in the neck (25%) and the axillae (15%). There are different types depending on the grade of fibrous, adipose and lymphatic tissue, on the other hand, by vascular proliferation (simplex, cavernous, cystic hygroma and different combinations).<sup>2,3</sup> Lymphangiomatous polyp is a form of manifestation of the lymphangioma with a different histology<sup>4</sup> and at the present time, there are not any malignant or recurrence cases in the literature,<sup>3</sup> but it is important to decide which course of action to take, mainly to be able to rule out other diagnoses such as hemangioma, mucous retention cyst, papilloma, fibroepithelial polyp, arteriovenous malformation, lymphangiectasia, juvenile nasopharyngeal angiofibroma and other lesions that could be malignant such as lymphoma.<sup>5</sup> In most cases in the literature, lymphangiomatous polyps have been unilateral in the tonsil, due to bilateral lymphangiomatous polyps of the palatine tonsils being very unusual.<sup>5</sup> The real incidence, predominance, age and sex are unknown and very variable in the existing literature, but the majority of the articles mentioned that the average age of the patient was 25.<sup>4</sup>

We have reported two different cases in young children, a unilateral lymphangiomatous polyp and bilateral lymphangiomatous polyps of the palatine tonsils, which are infrequent and uncommon according to the cases described in scientific publications.<sup>4</sup>

## CLINICAL CASES

### Case 1

In April 2018, a 6-year-old boy was referred to the pediatric otolaryngologist to assess a polypoid lesion in the right palatine tonsil that had

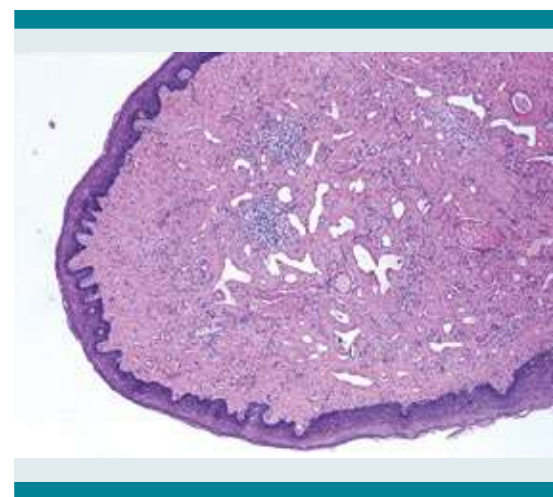
been found when the boy had tonsillitis. The boy had no other diseases and was asymptomatic.

In the oral cavity examination, a normal and symmetric size of the tonsils was observed, together with a polypoid lesion in the mucosa of the anterior pillar of the right tonsil of approximately 5-6 mm. The initial diagnosis was a papillomatous lesion. The rest of the physical ENT-examination was normal.

The lesion was removed in the operating room and was sent to the Department of Pathological Anatomy.

The Pathology Department received a tonsillectomy specimen which measured 8 x 6 x 4 mm. On the surface, there was a pedunculated polyp measuring 4 mm in the largest axis.

Histologically, the polypoid showed multiple vascular channels embedded in a fibrous stroma, with a few interspersed small lymphocytes. The vascular channels lacked muscular wall and endothelia were non-atypical. The surface epithelium did not show alterations. **Figure 1**



**Figure 1.** Low power field of the tonsillar lymphangiomatous polyp. Dilated vascular channels interspersed among a fibrous stroma with scarce interstitial lymphocytes. (H&E, 40x).

The IHC showed that the vascular channels were positive for endothelial (CD34, CD31) and lymphatic markers (D2-40), while being negative for WT-1. **Figure 2**

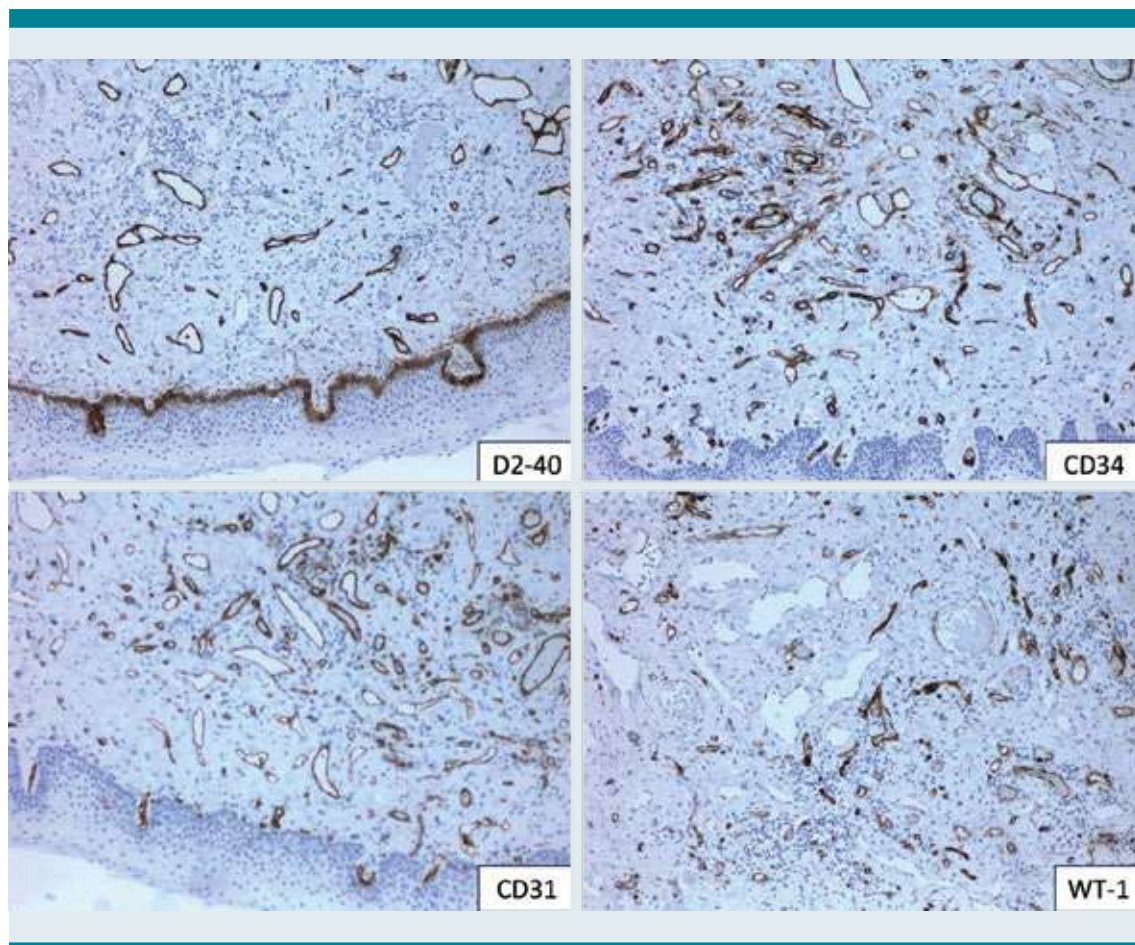
A diagnosis of tonsillar lymphangiomatous polyp was made.

It was decided to make the diagnosis of lymphangiomatous polyp of the tonsil to follow up for one year. The patient is currently having no detectable lesions and recurrences in tonsils.

## Case 2

The other case occurred in May 2021, a 3-year-old girl was referred by her pediatrician to the pediatric otolaryngologist due to the finding of a tonsil lesion of several months of duration. The only symptom which she had was dribbling. She did not have dysphagia, dysphonia or even dyspnea. She had no other pathologies.

In the physical exam, we observed a tonsillar asymmetry (grade II right tonsil and grade I left



**Figure 2.** Immunohistochemistry study of the tonsillar lymphangiomatous polyp. Vascular channels expressed endothelial (CD34 and CD31) and lymphatic markers (D2-40). WT-1 was negative.

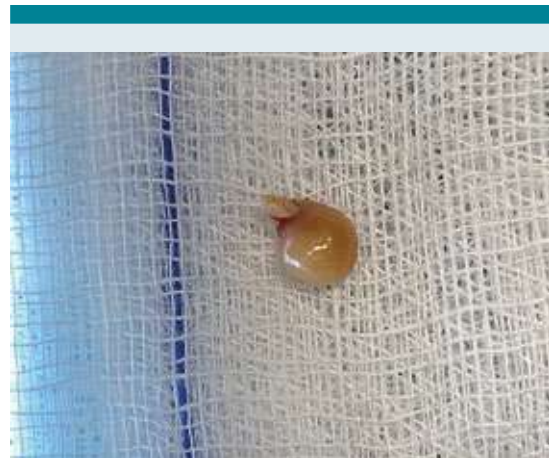

tonsil on the Friedman's scale) and a single pedunculated mass on the right superior tonsil without other findings. Nasofibroscopy was unremarkable. We decided to do a cervical MRI (**Figure 3**) before the tonsillectomy due to the possibility of vascular and lymphatic malformations. There was no evidence of cervical lymphadenopathy.

It was decided to remove the polyp (**Figure 4**) in the operating room with general anesthesia.

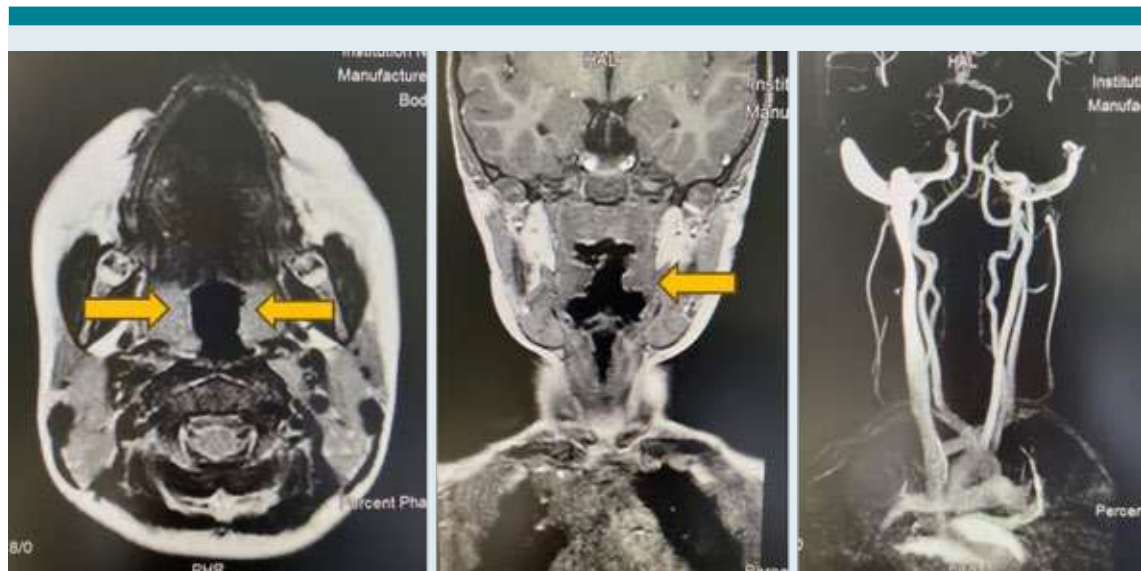The Pathology Department received a pedunculated polypoid lesion measuring 8 x 5 x 5 mm. The cut surface was too whitish and fleshy to perform a histologic analysis.

Histologically the lesion showed dilated vascular channels tightly packed with small lymphocytes without atypia (**Figure 5**). The stroma was fibrous and obscured by small lymphocytes. The surface epithelium showed variable spongiosis with focal lymphocytic permeation, and without epithelial

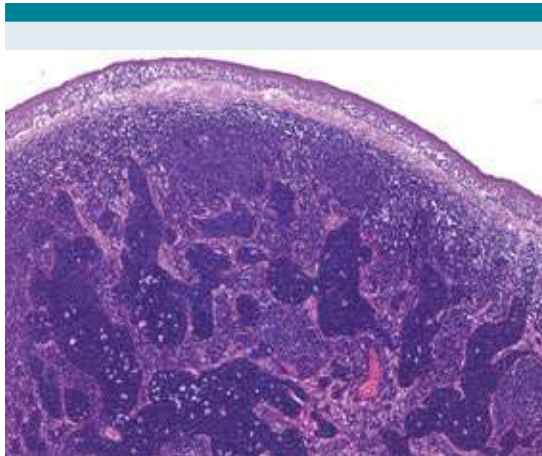


**Figure 4.** Macroscopic aspect of lymphangiomatous polyp of tonsil.

dysplasia. Some germinal centers were identified immediately below the epithelial surface. Macrophages with tangible bodies were found in both the lymphocyte-filled vascular channels and germinal centers.



**Figure 3.** Face and neck Magnetic Resonance Imaging (MRI) and Magnetic Resonance Angiography (MRA) of neck. Yellow arrows: palatine tonsils. Contrast is visualized in both supra-aortic trunks without vascular alterations or malformations.



**Figure 5.** Low power field of the tonsillar lymphangiomatous polyp. Vascular channels filled with small lymphocytes can be seen interspersed among a fibrous stroma with abundant interstitial lymphocytes. Spongiosis in the surface epithelium can be seen. (H&E, 40x).

IHC showed that the vascular channels were positive for both endothelial (CD34) and lymphatic (D2-40) markers. The lymphoid population filling the vascular channels was predominantly T CD3+, with occasional accompanying B CD20+ lymphocytes. Ki67 proliferation index was extremely low, in both intravascular and interstitial compartments. **Figure 6**

The final diagnosis was a tonsillar lymphangiomatous polyp.

Therefore, given the risk of other added vascular or lymphatic malformations, it was decided to carry out an imaging study of the patient prior to tonsillectomy surgery by means of cervical MRI, in order to prevent future complications during surgery.

The Pathology department received tonsillectomy pieces which measured 30 x 22 x 15 mm (right side) and 25 x 20 x 12 mm (left side). The right side showed a polypoid, fleshy surface.

Histologically, multiples areas with dilated lymphatic vessels filled with small lymphocytes, similar to the polypectomy specimen were found in both sides. Multiple lymphoid follicles, of different sizes were found in the rest of the tonsil. The lymphoid follicles tended to be smaller in the polypoid areas. IHC showed positivity of the endothelium for D2-40 and CD34.

A diagnosis of multiple tonsillar lymphangiomatous polyps and reactive follicular hyperplasia was made. A comment was made that given the multiple lesions found in both tonsils, it was not possible to confirm a recurrence of the lesion initially removed. **Figure 7**

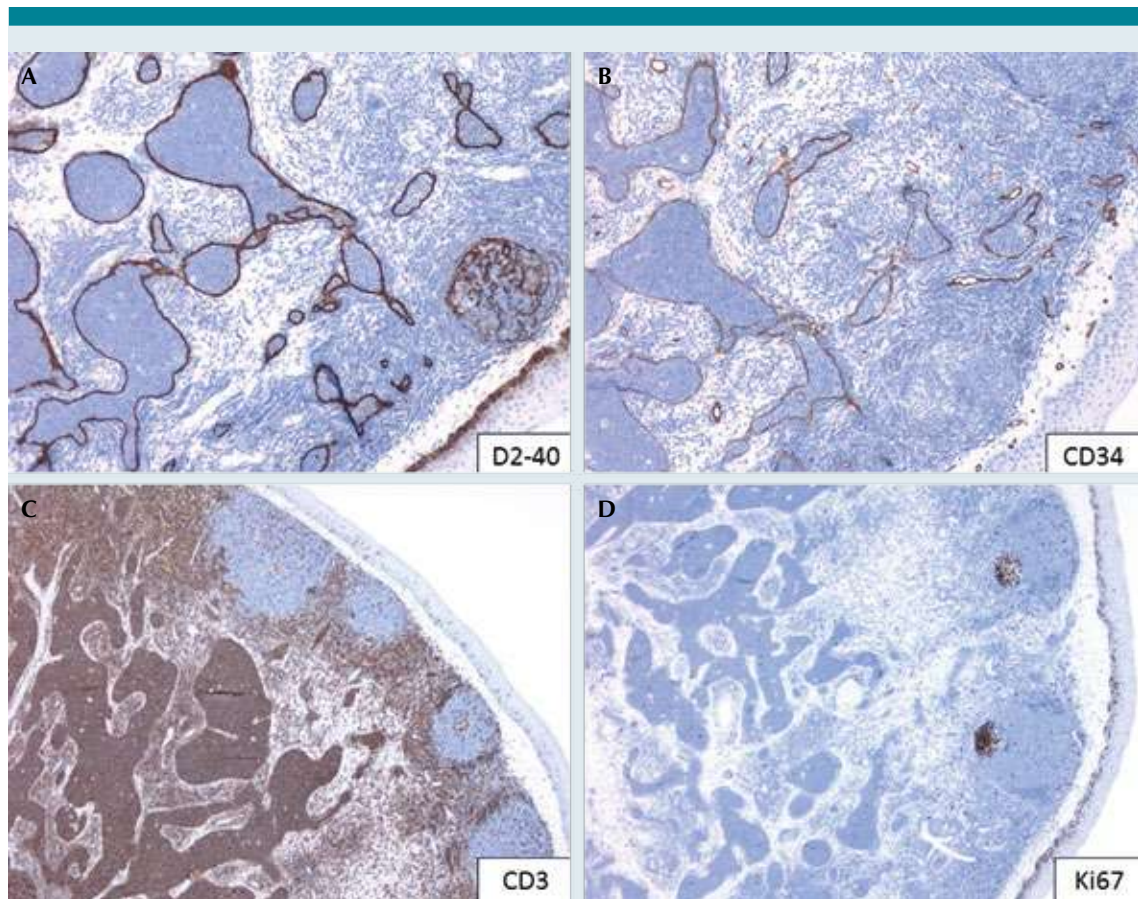
The adenoids measured 15 x 15 x 3 mm and had reactive follicular hyperplasia.

## DISCUSSION

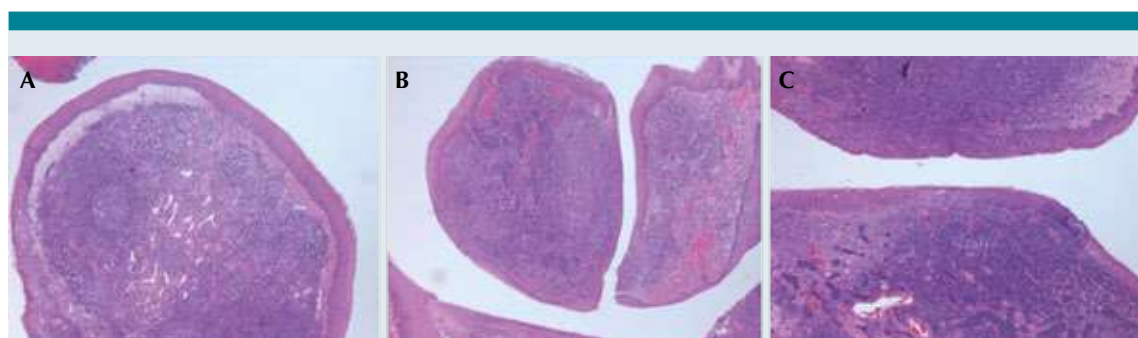
A lymphangiomatous polyp is a benign lesion,<sup>1-4</sup> however, some authors said that these are more typically located in the gastrointestinal tracts (colon, stomach and small intestine) and they affirmed that the palatine tonsils are the most prevalent place when the head and neck area is involved.<sup>4</sup> Meanwhile, others mentioned that 90% of all lymphangiomas are in the head and neck area and a less usual place is a tonsil.<sup>1</sup>

The incidence of this is variable in the different studies: 1,9% 1,8%, at the moment only 30 cases are reported in the literature.<sup>3-7</sup> Apart from these, another factor which can have an effect on the incidence, is the nomenclature used in the anatomical pathologic diagnosis for example: hamartomatous tonsillar polyp, angioma, angiofibroma, fibroangioma or polypoid lymphangioma of the tonsil.<sup>3,4,7</sup>

Regarding the sex, a gender predilection doesn't exist,<sup>4</sup> although one study mentioned male prevalence (3:1),<sup>8</sup> nevertheless, we present a female case.



**Figure 6.** Immunohistochemistry study of the tonsillar lymphangiomatous polyp. **A)** D2-40: Lymphatic markers. **B)** CD34: Vascular channels expressed endothelial. **C)** CD3: Small lymphocytes were predominantly CD3 positive, with few accompanying CD20 positive lymphocytes (not shown). **D)** Ki67 proliferation index was extremely low.



**Figure 7.** Histological study of the bilateral lymphangiomatous polyps of the palatine tonsils. **A)** Tonsillar lymphangiomatous polyp with limited lymphocytes. **B** and **C)** Healthy tissue of a tonsil.



The clinical symptoms depend on the size, location, and time progression: dysphagia, sore throat, dyspnea<sup>1,5,7</sup> and like in one of our patients, a very uncommon symptom: dribbling.

Nowadays the etiopathogenesis remains unknown. There are some hypotheses: chronic inflammation and obstruction of lymphatic channels, tonsillitis,<sup>4</sup> congenital malformations,<sup>2</sup> hamartoma,<sup>3</sup> a dusty or polluted environment<sup>9</sup>.

The presumption diagnosis is made during the clinical examination in the ENT appointment and the definitive diagnosis is only made following the histological study.<sup>5,9</sup>

The main differential diagnosis is with common benign lesions such as mucous retention cyst or papillomatosis.

Then the uncertainty is if these patients need an additional, more exhaustive study prior to the treatment, a CT scan or MRI to verify the benign lesion and the spread and enlargement of the polyp. The majority of the reported cases do not perform any image study before the surgery, although there is only one study that did it to fully rule out other lesions.<sup>10</sup> Furthermore, other authors such as Edward Park *et al*<sup>4</sup> and Henry H. Chen *et al*<sup>5</sup> did a CT scan on the patients in the postoperative to exclude other head and neck tumors and malformations.<sup>4,5</sup> Although the clinical behavior of tonsillar lymphangiomatous polyps is unknown and unclear regarding whether they can grow and expand or disappear over time,<sup>5</sup> our reported cases did not have presence of a malignancy or growth.

We present two different approaches to treat this type of polyps, in our first case, we only decided to remove the polyp and follow up the patient for one year without complications. On the other hand, with our second case, firstly we decided to do a simple surgical excision of the

polyp in the tonsil and following this, it was analyzed. Then, with the histological diagnosis, we decided to do a cervical MRI before the tonsillectomy due to the possibility of vascular and lymphatic malformations. We preferred an MRI to a CT scan, because the MRI has less radiation for children, and it lets you see the soft tissues better. This was done before the tonsillectomy to prevent complications.

Subsequently, the scientific proof in the literature was studied and finally, it was decided to remove the tonsils completely after talking jointly with her family, mainly to exclude other lesions inside of the tonsils, but before the surgery, it was decided to do a facial MRI to exclude other vascular malformations, thus helping to prevent other complications.

Although the MRI of the girl was normal, later, with the complete surgical resection of the tonsils, another diagnosis different to our initial one was made: bilateral lymphangiomatous polyps. For this reason, to maximize the chances of a successful outcome, the curative treatment for these polyps is a tonsillectomy.<sup>5,9,11</sup>

The follow-up performed in our patients was firstly, the first month after surgery, at 6 months and at one year. In both cases, there were no recurrences.

The discussion regarding the best treatment is not clear, although most of the authors such as Betul Peker *et al*,<sup>6</sup> and Edward Park *et al*<sup>4</sup> assert that simple surgical excision of the lesion is enough to treat the patient and they proved this with one year follow up without recurrences.<sup>2,3,4,7</sup>

As a result, more studies about the best way to manage this type of lesions are necessary.

Therefore, more studies with higher samples will be required to identify the best way to benefit patients.

## CONCLUSION

Lymphangiomatous polyp is a type of benign tumor of the tonsils which is very rare and uncommon. Although there is a lower risk of malignancy at present, a consensus does not exist about the best way to treat this condition and if a CT scan or MRI prior to the surgery or after it is necessary or not. Tonsillectomy is a curative surgery to eliminate the tumor. In both reported cases there was no evidence of malignancy or growth.

## Acknowledgements

We would like to thank the patient and her family who allowed us to use her case for this manuscript.

## REFERENCES

1. Kardon DE, Wenig BM, Heffner DK, Thompson LD. Tonsillar Lymphangiomatous Polyps: A Clinicopathologic Series of 26 cases. *Mod Pathol* 2000; 13 (10): 1128-33. <https://doi.org/10.1038/modpathol.3880208>
2. Raha O, Singh V, Purkayastha P. Lymphangoma tonsil-rare case study. *Indian J Otolaryngol Head Neck Surg* 2005; 57 (4): 332-334- <https://doi.org/10.1007/BF02907704>
3. Minzer S, Fernández L, Bravo G, Gallegos I. Lymphangiomas of adenoids and palatine tonsils: one case report. *Rev Otorrinolaringol Cir Cabeza Cuello* 2014; 74: 151-154. <http://dx.doi.org/10.4067/S0718-48162014000200010>
4. Park E, Pransky SM, Malicki DM, Hong P. Unilateral lymphangiomas of the palatine tonsil in a very young child: a clinicopathologic case report. *Case Rep Pediatr* 2011; 2011: 451542. <https://doi.org/10.1155/2011/451542>
5. Chen HH, Lovell MA, Chan KH. Bilateral lymphangiomas of the palatine tonsils. *Int J Pediatr Otorhinolaryngol* 2010; 74: 87-88. <https://doi.org/10.1016/j.ijporl.2009.08.017>
6. Hyams VJ. Differential diagnosis of neoplasia of the palatine tonsil. *Clin Otolaryngol Allied Sci* 1978; 3: 117-26. <https://doi.org/10.1111/j.1365-2273.1978.tb00674.x>
7. Cengiz BP, Acar M, Giritli E. A penunculated lymphangiomas of the palatine tonsil. A case report. *Braz J Otorhinolaryngol* 2013; 79 (3): 402. <https://doi.org/10.5935/1808-8694.20130069>
8. Balatsouras DG, Fassolis A, Koukoutsis G, Ganelis P, et al. Primary Lymphangioma of the tonsil: A case report. *Case Rep Med* 2011; 2011: 183182. <https://doi.org/10.1155/2011/183182>
9. Gan W, Xiang Y, He X, Feng Y, et al. A care-compliant article:Lymphangiomas of the palatine tonsils in a miner. *Medicine* 2019; 98 (1): e14009 <https://doi.org/10.1097/MD.00000000000014009>
10. Al Samarrae SM, Amr SS, Hyams VJ. Polypoid lymphangioma of the tonsil: report of two cases and review of the literature. *J Laryngol Otol* 1985; 99 (8): 819-823. <https://doi.org/10.1017/s0022215100097747>
11. Roth M. Lymphangiomas of the palatine tonsil. *Otolaryngol Head Neck Surgery* 1996; 115 (1): 172-3. [https://doi.org/10.1016/S0194-5998\(96\)70160-2](https://doi.org/10.1016/S0194-5998(96)70160-2)